



CASE REPORT

Medium Cut-Off Membrane Can Be a New Treatment Tool in *Amanita phalloides* Poisoning

Bülent Huddam, MD¹; Alper Alp, MD¹; İsmail Kırılı, MD²; Mehmet Yılmaz, MD²; Aytuğ Çağırtekin, MD²; Hakan Allı³; Sultan Edebali, MD²

¹Department of Nephrology, Faculty of Medicine, Mugla University, Mugla, Turkey; ²Department of Internal Medicine, Faculty of Medicine, Mugla University, Mugla, Turkey; ³Department of Biology, Faculty of Science and Arts, Mugla University, Mugla, Turkey

Mushroom poisoning is a common health problem that can be seen seasonally and geographically. Most mushroom poisoning requiring treatment worldwide is due to *Amanita phalloides*. Although liver failure and kidney injury are frequent, poisoning can also lead to more serious clinical situations, such as shock, pancreatitis, encephalopathic coma, cardiac failure, disseminated intravascular coagulation, and multiple organ dysfunction syndrome, and may cause death. In addition, when standard treatment approaches fail, extracorporeal treatment methods are often used. We report 2 cases in which hemodialysis with medium cut-off membrane was performed. We observed an improvement in liver and kidney function in both of our cases. The first case recovered, but the second case proved fatal owing to *Acinetobacter* sepsis, despite an improvement in renal function. Medium cut-off membrane hemodialysis may be an alternative option in the treatment of *Amanita phalloides* poisoning.

Keywords: mushroom poisoning, hemodialysis, dialyser, extracorporeal treatment, acute kidney injury, intoxication

Introduction

Amanita phalloides (AP) is responsible for more than 90% of mushroom poisonings resulting in death.¹ The presentation of AP poisoning can vary from subclinical status to fulminant hepatitis and death. Typically, the presentation follows a 4-stage clinical course: a symptomatic period (symptoms occur 6–8 h after oral intake); severe gastrointestinal symptoms, with nausea, vomiting and watery diarrhea, dehydration, renal injury, and electrolyte disturbances (up to the first 24 h); the development of hepatorenal syndrome and liver damage (24–48 h); and, finally, the terminal period, in which fulminant liver failure, hemorrhage, coma, and death can occur.

In the standard treatment approach, oral decontamination with activated charcoal, intravenous hydration,

N-acetyl cysteine (NAC), silibinin, and penicillin are recommended. Numerous extracorporeal methods have been described in the literature, with varying results. Initiating these treatments in the first 48 h is extremely important in terms of clinical prognosis.² Medium cut-off (MCO) membranes are a new type of hemodialysis membranes that have been used more frequently in past decade. They have the advantage of clearing higher-molecular-weight toxins and offer beneficial effects in the management of sepsis and inflammation. It has been shown that the mortality rate may decrease by up to 9% in patients who have received intervention in the first 48 to 72 h in mushroom poisonings.³ Despite standard treatments, most patients require liver transplantation.

Case 1

Mugla is situated in the southwest of Turkey and is a province dominated by the Mediterranean climate (37°12'54.8"N, 28°21'49.4"E). It is estimated that about 50 species of mushrooms are present in this region.

An 81-year-old local woman presented to the emergency department with nausea, vomiting, and diarrhea. She had

Corresponding author: Alper Alp, MD, Mugla Sitki Kocman University, School of Medicine, Department of Nephrology, Kötekli Mahallesi, Marmaris Yolu üzeri, No: 48, Menteşe /MUĞLA, Mugla, Turkey; e-mail: alperalp@mu.edu.tr.

Submitted for publication June 2020.

Accepted for publication December 2020.

Table 1. Laboratory values on admission

Values	Case 1	Case 2
Glucose (74–109 mg·dL ⁻¹)	172	115
Urea (16.6–48.5 mg·dL ⁻¹)	76.3	19.9
Na (136–145 mmol·L ⁻¹)	134	142
K (3.5–5.1 mmol·L ⁻¹)	3.8	4.43
Calcium (8.6–10 mg·dL ⁻¹)	7.9	7.9
Chloride (98–107 mmol·L ⁻¹)	92	105.6
Albumin (35–52 g·L ⁻¹)	31	32
GGT (6–42 U·L ⁻¹)	72	55
ALP (35–105 U·L ⁻¹)	129	86
LDH (135–214 U·L ⁻¹)	687	472
d-dimer (0–500 ng·mL ⁻¹)	882	-
Hemoglobin (11.2–19.9 g·dL ⁻¹)	10.2	14.2
APTT (22–34.5)	75	25.5

ALP, alkaline phosphatase; APTT, activated partial thromboplastin time; GGT, gamma-glutamyl transferase; LDH, lactate dehydrogenase.

a history of eating mushrooms she collected from the Dikmen mountain (near the village of Fadil, at an altitude of 660 m [2165 ft] above sea level) 4 d prior. On physical examination, her blood pressure was 110/70 mm Hg, heart rate was 105 beats·min⁻¹, respiratory rate was 17 breaths·min⁻¹, and body temperature was 36.9°C. She was lethargic, and auscultation of the lungs revealed bilateral rales in the lower lung fields and bilateral 1+ pretibial edema.

On admission, laboratory findings revealed elevated hepatic enzymes and acute kidney injury (Table 1, Figures 1 and 2). When we examined the mushrooms that were collected, we found that they were an AP type. During follow-up, progression was observed in some laboratory values: aspartate aminotransferase (AST) 10564 IU·L⁻¹, alanine transaminase (ALT) 4922 IU·L⁻¹, total bilirubin 2.5 mg·dL⁻¹, direct bilirubin 1.8 mg·dL⁻¹, international normalized ratio (INR) 3.99, and activated partial thromboplastin time (APTT) 44.2 s. According to the progression and physical examination findings, the patient, who had an oliguric course, underwent hemodialysis (HD) with MCO membrane (Theranova, Baxter Healthcare, Deerfield, IL, USA) and other standard treatments (oral activated charcoal, intravenous hydration, NAC, penicillin, silymarin). The patient received a total of 17 sessions of HD, and significant improvement in clinical status and laboratory values was seen. The patient's urine output increased, and she was followed up for 22 d without additional HD. She was later removed from HD totally and discharged. On discharge, laboratory values were as follows: urea 100 mg·dL⁻¹, creatinine

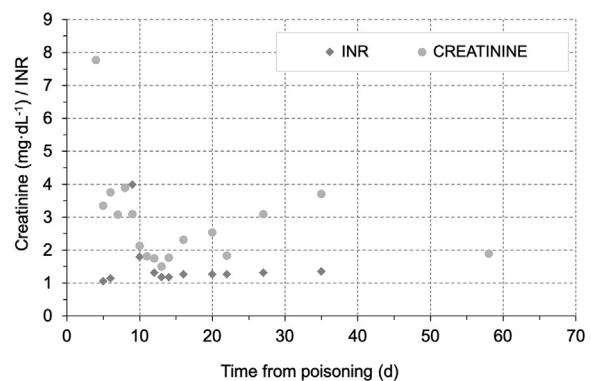
2.0 mg·dL⁻¹, AST 11 IU·L⁻¹, ALT 5 IU·L⁻¹, total bilirubin 1.2 mg·dL⁻¹, direct bilirubin 0.79 mg·dL⁻¹, INR 1.12, and APTT 32 s.

Case 2

A 57-y-old woman presented to the emergency department with nausea and vomiting. The patient, who was the daughter-in-law of the first case and had been living in the same house, had consumed the same mushrooms. She presented to our hospital 2 d (5 d after eating the mushroom) after her mother-in-law's hospital admission. She had no history of chronic disease.

On admission, her blood pressure was 120/80 mm Hg, heart rate was 85 beats·min⁻¹, body temperature was 36.5°C, and respiratory rate was 13 breaths·min⁻¹. Laboratory values revealed high serum transaminase levels, but renal function tests were within normal limits (Table 1, Figures 3 and 4). On the second day of follow-up, her renal function deteriorated and she became anuric. In addition to other standard treatments (oral activated charcoal, intravenous hydration, NAC, penicillin, silymarin), HD was initiated with MCO membrane (Theranova, Baxter Healthcare). The patient was intubated on the third day.

A total of 4 sessions of HD were performed. From the fourth day of treatment, the patient's transaminases and renal function tests started to improve, and urine output started to increase. Although recovery in liver and kidney function was observed, the patient's acute-phase reactants progressed and fever developed. *Acinetobacter baumani* reproduction occurred in the tracheal aspirate culture, and antibiotherapy was modified. During follow-up, septic conditions could not be controlled, and on the seventh day of treatment she died of cardiac arrest related to septic shock.

**Figure 1.** The course of creatinine and INR levels in case 1.

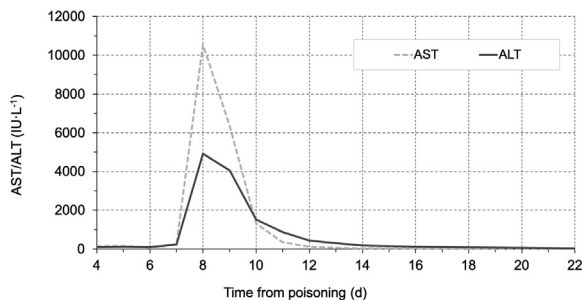


Figure 2. The course of hepatic enzymes in case 1.

Discussion

Mushroom consumption is increasing in both rural and urban areas secondary to developments in gastronomy. In particular, mushrooms consumed in rural areas can lead to fatal poisonings owing to careless and misinformed approaches to collection.

Amanitin group mushrooms are the most poisonous mushroom species and are assumed to comprise 90% of the species that cause human death globally. AP constitutes the majority of these. In a retrospective study analyzing 93 mushroom poisonings between 1990 and 2008 in Portugal, 63% were dependent on the amatoxin type and 12% ended in mortality.⁴ AP contains 3 toxin groups: phallotoxins, virotoxins, and amatoxins. Amatoxins, which are cyclic octapeptides, consist of 9 different components. In the main mechanism of action of the main toxin, α amatoxin is to bound covalently to RNA polymerase II, causing transcription inhibition and leading to protein synthesis disorders. The lethal human dose of amatoxins is 0.1 to 0.3 mg·kg⁻¹. This is a very low concentration and can often be found in a single mushroom. Amatoxin is absorbed through the gastrointestinal system; it is rapidly eliminated from the blood and disperses to the liver and kidneys within 48 h.

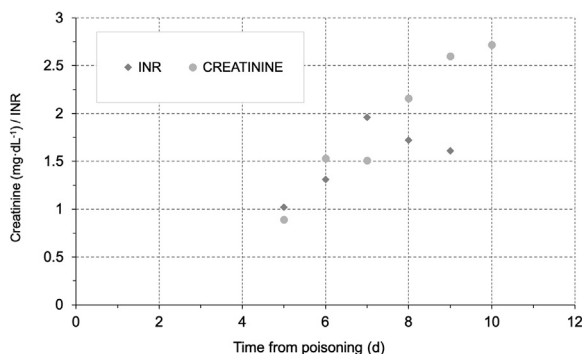


Figure 3. The course of creatinine and INR levels in case 2.

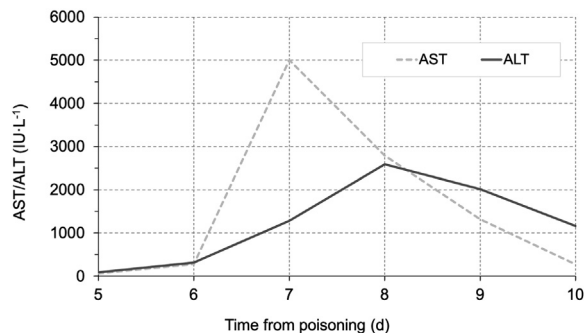


Figure 4. The course of hepatic enzymes in case 2.

Because of this rapid absorption and distribution, it may be difficult to detect in plasma after 36 to 48 h. Approximately 60% of circulating amatoxins pass into bile and enterohepatic circulation, and the remaining 40% are cleared by the renal route. This metabolism explains the renal and hepatotoxicity commonly observed with these types of amatoxin mushroom ingestions.⁵ Both of our patients consumed this type of mushroom by cooking it in boiling water, which was then drunk. The mushrooms were collected by the patients' relatives, brought to the emergency department, and later identified as AP by an expert mycologist (Figure 5).

Survival is primarily related to the degree of liver damage, but other potential complications are also very important. The major effect is due to liver necrosis (centrilobular and periportal, hemorrhage), which rapidly develops into both renal and liver dysfunction (hepatorenal syndrome). An increase in ammonia levels can lead to coma and convulsions. This may be followed by respiratory failure and hemorrhage.

In rat studies, it has been shown that concentration in renal tissue is much higher than that in liver tissue. In autopsy studies, macroscopically, cortical extravasation in the kidneys, diffuse hemorrhagic stasis, acute tubular necrosis (ATN), and tubular dense hyaline cylinders were observed histopathologically. Degenerative findings such as necrosis, vacuolization and edema, atrophy in the distal tubule, intratubular protein-rich cylinders, and thickening in the Bowman's outer capsule were found in renal biopsy studies. Experimentally, polymyxin B, by inhibiting the effect of α a-amanatin, significantly prevented the occurrence of these findings in rats and decreased mortality.⁵ There were various levels of inflammatory and oxidative changes in rat studies (lymphocytic infiltrations, hydropic degeneration) and histopathologically brushy border loss as the applied dose increased, and necrotic areas have been shown to increase even more.⁶



Figure 5. *Amanita phalloides*.

In the standard treatment of mushroom poisoning, activated charcoal, penicillin-G, corticosteroid, NAC, and silibine treatments are advised to reduce absorption from the gastrointestinal tract in the acute period.² Because excretion is mainly through urine, force diuresis has been recommended by some studies, especially to provide renal clearance in the first 48 h. However, considering the clinical conditions that reduced renal perfusion (hepatorenal syndrome, ATN), in these particular cases, we advised against this intervention.

Regarding extracorporeal treatment options for patients with acute liver failure in AP ingestions, successful treatment with the molecular adsorbent recirculation system (MARS) and fractional plasma separation and adsorption system (FPSA) has been reported.^{7,8} It was shown that MARS treatment can decrease mortality and decrease urea-creatinine levels in this patient group.⁹ Positive results with FPSA also were reported.⁸ A retrospective analysis of 81 patients with both liver and renal injuries secondary to AP intoxication who underwent different dialysis methods (HD, hemoperfusion [HP], plasmapheresis [PF]) found that although 16 fatal cases had ATN, none died of renal causes.¹⁰ Again, in a study comparing patients with fatal and nonfatal intoxication, no significant difference in creatinine levels was observed between the groups.¹¹

In recent decades, a new-generation membrane type called an MCO membrane has been popular owing to its new potential utilities in HD.¹² These membranes, by diffusion and convection, increase the permeability of medium-large toxins (up to 45 kDa molecular weight) owing to their higher pore sizes, allowing more and different uremic toxins to be removed. It has been reported that MCO membranes are more advantageous than high-flux HD in removal of some medium-molecular-weight toxins.¹³ In recent studies of the use of MCO dialyzer in HD patients, molecules such as β 2-microglobulin, light chains without kappa/lambda, complement factor D, and α 1-microglobulin have been effectively removed, as well as expression of sepsis/inflammation-associated inflammatory markers such as TNF- α , mRNA- α , and IL-6 mRNA; levels of STNFR1 also have been shown to be reduced.

We intervened with emergent HD with an MCO membrane in both of our cases and successfully treated the first patient. In our second case, improvement in renal and liver function was achieved, but the patient died of sudden cardiac arrest related to septic shock. Because of the late clinical findings (at least 6–8 h) in AP poisonings, there is often a delay in hospital admission. Both of our patients delayed their presentation to our emergency department after consumption of the mushroom. However, in our first case, full resolution was achieved 48 h

after the first case, and the second case proved fatal owing to the late admission.

In a report of 2 patients with acute intoxication, 1 was treated for 72 h with continuous veno-venous hemofiltration (CVVH) and 3 plasma perfusions and the other with 100 h of CVVH and 5 doses of activated charcoal HP, and both cases fully healed.¹⁴ Again, 2 cases who had combined therapy (HP + HD) completely recovered.¹⁵ In a study in which 21 patients were evaluated, PF was applied to all, and mortality was nearly 5%, lower than the average in the literature.¹⁶ In another report, beneficial effects of the combined use of extracorporeal therapies were emphasized. In this report, the effectiveness of FPSA and PF was demonstrated; continuous renal replacement therapy was used only to treat uremic status and elevated ammonia.² Many extracorporeal toxin removal treatments (HD, HP, PF) appear to be effective, especially in the first 48 h of exposure. The effectiveness of systems such as MARS and FPSA has been demonstrated in AP poisoning, especially in liver failure. However, an important disadvantage is that these types of interventions can only be performed at major tertiary care centers, and as the highest clinical efficacy is within the first hour after ingestion, this level of care cannot be applied in every center.

Mushroom poisoning is a common and possibly fatal health problem. It is extremely important to diagnose early and begin treatment as soon as possible, especially because early HD has been reported to significantly reduce mortality resulting from liver and kidney failure.¹⁷ There are currently no specific antidotes or guidelines for treatment, so starting extracorporeal treatment methods as early as possible in addition to standard treatments can be considered as a method that reduces mortality and morbidity. Since the 1960s and 1970s, dialysis modalities have been tried in AP poisoning. Although the treatment of AP ingestion with extracorporeal methods seems rational, the most effective modality has not yet been clarified. Considering that special extracorporeal detoxification methods can be performed in a tertiary or quaternary care center, it is very important to start treatment in the first 24 to 48 h, until transport is provided. Additionally, we recommend that the HD MCO membrane be considered as a life-saving treatment modality for these types of mushroom poisonings. To our knowledge, these 2 cases represent the first documentation in the medical literature describing HD with MCO membrane in acute AP mushroom poisoning.

Acknowledgments: We are grateful to Doruk Demircioglu for his technical support.

Author Contributions: All authors contributed equally to the writing of this manuscript and take responsibility for the final form of the manuscript.

Financial/Material Support: None.

Disclosures: None.

References

1. Ye Y, Liu Z. Management of *Amanita phalloides* poisoning: a literature review and update. *J Crit Care*. 2018;46:17–22.
2. Kieslichova E, Frankova S, Protus M, Merta D, Uchytlova E, Fronck J, et al. Acute liver failure due to *Amanita phalloides* poisoning: therapeutic approach and outcome. *Transplant Proc*. 2018;50(1):192–7.
3. Saviuc P, Flesch F. Acute higher fungus mushroom poisoning and its treatment. *Presse Med*. 2003;32(30):1427–35.
4. Brandão JL, Pinheiro J, Pinho D, da Silva DC, Fernandes E, Fragoso G, et al. Intoxicação por cogumelos em Portugal [Mushroom poisoning in Portugal]. *Acta Med Port*. 2011;24(Suppl 2):269–78.
5. Garcia J, Costa VM, Carvalho ATP, Silvestre R, Duarte JA, Dourado DFAR, et al. A breakthrough on *Amanita phalloides* poisoning: an effective antidotal effect by polymyxin B. *Arch Toxicol*. 2015;89(12):2305–23.
6. Ergin M, Dunder ZD, Kilinc I, Colak T, Oltulu P, Girisgin AS. Alpha-amanitin poisoning, nephrotoxicity and oxidative stress: an experimental mouse model. *Iran Red Crescent Med J*. 2015;17(8):e28068.
7. Stankiewicz R, Lewandowski Z, Kotulski M, Patkowski W, Krawczyk M. Effectiveness of fractionated plasma separation and adsorption as a treatment for *Amanita phalloides* poisoning. *Ann Transplant*. 2016;21:428–32.
8. Bergis D, Friedrich-Rust M, Zeuzem S, Betz C, Sarrazin C, Bojunga J. Treatment of *Amanita phalloides* intoxication by fractionated plasma separation and adsorption. *J Gastrointest Liver Dis*. 2012;21(2):171–6.
9. Sorodoc L, Lionte C, Sorodoc V, Petris O, Jaba I. Is MARS system enough for *A phalloides*-induced liver failure treatment? *Hum Exp Toxicol*. 2010;29(10):823–32.
10. Mydlik M, Derzsiova K. Liver and kidney damage in acute poisonings. *BANTAO J*. 2006;4(1):30–3.
11. Escudie L, Francoz C, Vinel JP, Moucari R, Cournot M, Paradis V, et al. *Amanita phalloides* poisoning: reassessment of prognostic factors and indications for emergency liver transplantation. *J Hepatol*. 2007;46(3):466–73.
12. Boschetti-de-Fierro A, Voigt M, Storr M, Krause B. MCO membranes: enhanced selectivity in high-flux class. *Sci Rep*. 2015;5:18448.

13. Kirsch AH, Lyko R, Nilsson LG, Beck W, Amdahl M, Lechner P, et al. Performance of hemodialysis with novel medium cut-off dialyzers. *Nephrol Dial Transplant*. 2017;32(1):165–72.
14. Splendiani G, Zazzaro D, Di Pietrantonio P, Delfino L. Continuous renal replacement therapy and charcoal plasmapheresis in treatment of amanita mushroom poisoning. *Artif Organs*. 2000;24(4):305–8.
15. Mullins ME, Horowitz BZ. The futility of hemoperfusion and hemodialysis in *Amanita phalloides* poisoning. *Vet Hum Toxicol*. 2000;42(2):90–1.
16. Jander S, Bischoff J. Treatment of *Amanita phalloides* poisoning: I. retrospective evaluation of plasmapheresis in 21 patients. *Ther Apher*. 2000;4(4):303–7.
17. Mendonca S, Gupta S, Gupta A. Extracorporeal management of poisonings. *Saudi J Kidney Dis Transpl*. 2012;23(1):1–7.